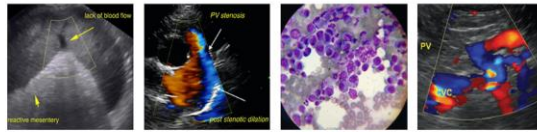


IMAGING PERFORMED BY

PAMobileVet.com 443-794-4700



EDUCATIONAL TELECONSULTATION SERVICES™

1-800-838-4268 info@sonopath.com SonoPath.com

**PATIENT PRESENTING CLINICAL SIGNS**

Sam Fredericks

History: 2/6 murmur, pre op

**SPECIES ECHOCARDIOGRAPHIC FINDINGS**

Canine

2D, M-mode, and Doppler study.

**BREED**

Greyhound

Left atrial size is normal. The mitral valve is normal. Left ventricular dimensions are normal. Left ventricular systolic function is normal. The aorta and aortic valve appear normal, though there is mildly increased flow velocity in the ascending aorta. Right atrial and right ventricular dimensions are normal. The tricuspid valve is normal. The pulmonary artery and pulmonic valve are normal. No shunting lesions are visualized. No pericardial effusion or cardiac masses are seen.

**SEX**

Male Neutered

LA - 45.6 mm  
LVIDd - 44.8 mm  
LVIDs - 29.7 mm  
FS - 33.7%  
LVOT - 1.65 m/s  
RVOT - 1.47 m/s

**AGE**

9 years

**WEIGHT**

72#

**ASSESSMENT/RECOMMENDATIONS**

Normal echocardiogram

**INTERPRETED BY**

Keith Blass, DVM, MS, DACVIM

This examination demonstrates no evidence of structural heart disease. Sam's murmur appears to be due to the presence of mildly increased flow velocity in his aorta, which is a common reason for a functional/innocent murmur to develop in dogs.

Sam's cardiovascular risk for general anesthesia is not increased based on this exam, and there are no contraindications to the use of any specific anesthetic agents.

**IMAGING PERFORMED BY**

Rebekah Jakum, CVT ARDMS/RVT

No therapy is recommended based on this exam.

A recheck echocardiogram is recommended if the characteristics of Sam's murmur change, or if other new physical exam and/or clinical abnormalities suggestive of cardiac dysfunction develop.

**HOSPITAL NAME**

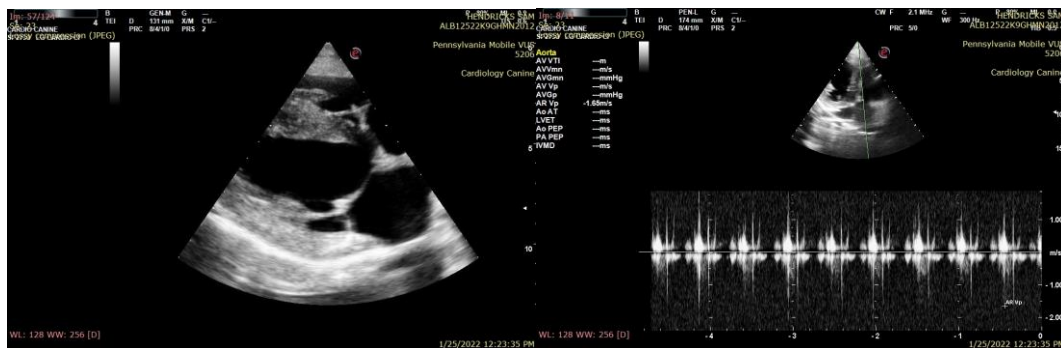Alburtis AH

**REFERRING VET**

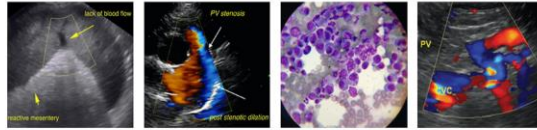
Dr. Smith

**DATE**

1.25.2022



The information and recommendations provided are based on the images presented by the referring veterinarian. No evaluation can be communicated regarding pathology that was not visible in the



**PATIENT** image/video clips provided.

Sam Fredericks Thank you for this referral. If the clinical or image interpretation does not parallel your findings or if I can be of any further assistance please contact me.

**SPECIES**

Canine **Keith Blass, DVM, MS, DACVIM (Cardiology)**

KeithBlass@gmail.com

**BREED** 631-804-5754

Greyhound

**SEX**

Male Neutered

**AGE**

9 years

**WEIGHT**

72#

**INTERPRETED BY**

Keith Blass, DVM,  
MS, DACVIM

**IMAGING  
PERFORMED BY**

Rebekah Jakum, CVT  
ARDMS/RVT

**HOSPITAL NAME**

Alburtis AH

**REFERRING VET**

Dr. Smith

**DATE**

1.25.2022